

## Non-surgical treatment of pulpitis, including those with history of spontaneous pain, using a combination of antibacterial drugs

Toyohiko Takushige<sup>1,3</sup>, D.D.S., Ph.D., Edward Venzon Cruz<sup>1,2</sup>, D.D.S., Ph.D., Md. Ali Asgor Moral<sup>1,2</sup>, D.D.S., Ph.D., Etsuro Hoshino<sup>1,2</sup>, D.D.S., Ph.D.

Oral Ecology in Health and Infection<sup>1</sup> and Cariology Research Unit<sup>2</sup>, Niigata University Graduate School of Medical and Dental Sciences, Niigata, Japan, and Takushige Dental Clinic<sup>3</sup>, Sendai, Japan

### Abstract

This is a retrospective clinical study of 360 teeth diagnosed with pulpitis and treated locally with a combination of three antibacterial drugs (ciprofloxacin, metronidazole and minocycline, "3Mix-MP") without a pulpectomy procedure. Consecutive patients with a clinical diagnosis of pulpitis had pre-operative factors collected (spontaneous pain, pulp exposure, depth of carious lesion) and were treated by placement of 3Mix-MP onto the pulpal floor of the carious lesion where softened dentin was intentionally left, if any was present. The treated lesions were then sealed by glass-ionomer cement and restored by resin inlays. A good clinical outcome was defined as the lack of any spontaneous pain, no mechanical allodynia to biting and the presence of pulpal responsiveness to cold or electrical stimuli. Using these criteria, a good clinical outcome was found in 342 (95%) of the 360 cases. Six cases progressed to pulpal necrosis and the remaining 12 cases required re-treatment using the same 3Mix-MP, resulting in a subsequent good outcome. Recalcification of softened dentin was evident on postoperative radiographs. These data suggest that 3Mix-MP may be worth evaluating in prospective randomized clinical trials for treatment of pulpitis including cases of so-called "irreversible" pulpitis.

### Key words:

3Mix-MP, LSTR 3Mix-MP, SavePulp Therapy, pulpitis with spontaneous pain

### Introduction

Most cases of pulpitis are associated with bacteria. Bacteria present in carious lesions, together with reactive inflammatory and immunological host responses, lead to the clinical development of pulpitis. Using this conceptual framework, bacterial constituents of carious dentin (1), pulpitis lesions (2), infected root dentin and necrotic pulps (3, 4), periapical lesions and infected cementum (5) have been analyzed under strict anaerobic conditions to understand which bacteria are present in these lesions. In addition, bacteria at other oral sites, including dental plaque (6), tongue plaque (7), denture plaque (8), saliva (9), periodontal pockets (10) and osteomyelitis sites (11) have been also analyzed with strict anaerobic procedures because these were possible sources of bacteria invading pulpal lesions. These studies included a large number of the "difficult to culture" species of bacteria (12). Importantly, all of these bacteria were found to be sensitive against a combination of three antibacterial drugs, namely ciprofloxacin, metronidazole and minocycline (5, 13-21), together with other combinations (17).

These findings led to a new hypothesis for treating these infections. The 'Lesion Sterilization and Tissue Repair' (LSTR) hypothesis proposes that removal or disinfection of bacteria present in these lesions by local application of an antibacterial drug combination may lead to resolution of dentinal, pulpal and periapical lesions (21). The repair of damaged lesions can be expected when lesions are fully disinfected. Further, affected dentin that is clinically softened upon probing could be re-calcified after disinfection (14), and, so, affected dentin could be intentionally left in a carious lesion. In addition, when 3Mix (i.e., ciprofloxacin, metronidazole and minocycline) was mixed with macrogol (M) and propylene glycol (P), the combination has been demonstrated to penetrate efficiently dentinal lesions via dentinal tubules (22), suggesting that bacteria in pulpal lesions could be killed by placement of 3Mix-MP at the bottom

of a carious lesion. Thus, one important prediction of the LSTR hypothesis is that local delivery of effective antibiotics in an appropriate vehicle to a carious lesion may lead to healing of cases of irreversible pulpitis without a need for conventional pulpectomy procedures. The aim of this retrospective clinical study was to evaluate the clinical outcomes of this hypothesis by following up cases of irreversible pulpitis treated by local application of 3Mix-MP, which is called as "LSTR 3Mix-MP SavePulp therapy".

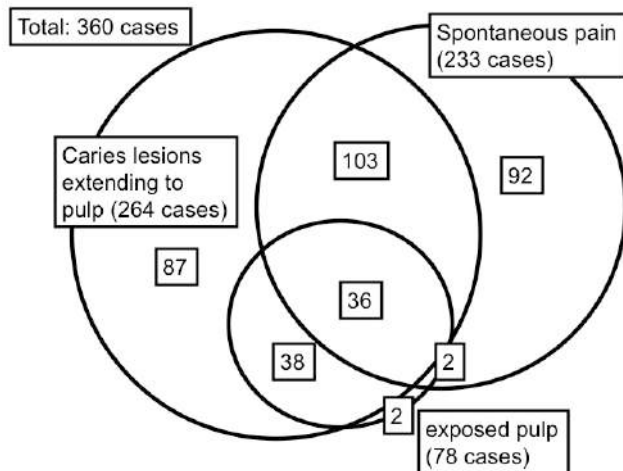
### Materials and Methods

#### *Patients and teeth involved in this study*

Each of the patients visited the Takushige Dental Clinic for dental treatment. Prior to their inclusion to this study, they were informed of the aim, expected clinical results, as well as the risks and alternatives of the treatment, and they subsequently completed an IRB approved informed consent. The patients were treated by one of the four dentists in the clinic.

The diagnosis of pulpitis required the presence of a carious lesion extending to the pulp chamber upon radiographic or clinical examination, or the combination of a deep carious lesion with spontaneous pain. Although this diagnosis conforms to the classic definition of "irreversible pulpitis", we have classified this as "pulpitis" in this study in accordance with the LSTR hypothesis. The distribution of these clinical findings in the 360 cases is presented in Fig. 1. A total of 268 teeth had pulp exposure and this included 264 cases of radiographically evident carious dentin extending to the pulp chamber as well as a subset of 74 teeth with clinically evident pulp exposure; 4 additional teeth had pulp exposures that were clinically but not radiographically evident. A total of 233 teeth had carious lesions with spontaneous pain. Some cases were comprised of a combination of these criteria (Fig. 1).

Fig. Pulpitis cases treated by LSTR 3Mix-MP SavePulp therapy.



### Clinical and radiographic observations

Clinical symptoms, such as swelling, abscess, sinus tract, induced pain on cold and hot conditions, pain on bite, spontaneous pain, were recorded before and after the treatment. Preoperative radiographs were taken prior to treatment to observe development of caries lesions to pulp chambers and periodontium conditions. Postoperative radiographs were also taken to observe re-calcification of softened dentin, closure of exposed pulps, and radiographic changes in periradicular lesions.

### Preparation of 3Mix-MP

Commercially prepared chemotherapeutic agents, namely, ciprofloxacin (Ciproxan, Bayer, Osaka, Japan), metronidazole (Trichocide, Green Cross, Osaka, Japan) and minocycline (Minomycine, Ledea-Japan, Tokyo, Japan) were used. Preparation procedures of 3Mix-MP were described elsewhere (21, 23, 24). In short, after removal of the capsules or coating materials that enclose the drug products, each of the drugs was pulverized to fine powders using porcelain mortars and pestles, and then stored separately in a tightly capped porcelain container to prevent exposure to light and humidity. A small amount of silica gel in a bag was placed inside the container to maintain low humidity. The powdered drugs were used within a month of preparation. On the day of treatment, powdered ciprofloxacin, metronidazole and minocycline were mixed in a ratio of 1:3:3 (by volume). The vehicle, of an ointment consistency, was prepared separately by mixing macrogol (M; Solbase, Meiji, Tokyo, Japan) and propylene glycol (P) in a ratio of 1:1 (by volume). The 3Mix antibiotics and MP vehicle were thoroughly mixed to form 3Mix-MP in a ratio of 7:1 for standard consistency and, then, ball-like particles (1 mm diameter) of 3Mix-MP were prepared. 3Mix-MP preparation should be prepared and used on the day of preparation.

### Clinical procedure of LSTR therapy for pulpitis

The clinical procedures are described elsewhere (23). In brief, previous restoration, if any, was removed. Softened dentin was not removed intentionally unless the access cavity was <1.5 mm in depth in dentin. Care was taken not to damage the pulp during the preparation. The dentinal walls of the preparation were treated with 12% EDTA for 1 min to remove the smear layer. In pulpitis cases without visible pulp exposure, the 3Mix-MP placed on the bottom of caries cavities for local disinfection. In pulpitis cases with visible pulp exposure or accidental pulp exposure, the additional removal of carious

dentin was stopped to prevent expansion of the size of the pulp exposure. The exposed pulps were chemically cleaned with NaClO gel (AG Gel, GC, Tokyo, Japan) and further disinfected by 3Mix-MP placed on the dentine floor of the cavities. 3Mix-MP was not placed directly onto exposed pulp. Patients were not anesthetized with local anesthesia, because the above procedures do not give pain to patients. Under anesthetized conditions, dentists may not recognize damaging the pulps and giving pain to patients.

MP placed on the bottom of caries cavities for local disinfection. In pulpitis cases with visible pulp exposure or accidental pulp exposure, the additional removal of carious dentin was stopped to prevent expansion of the size of the pulp exposure. The exposed pulps were chemically cleaned with NaClO gel (AG Gel, GC, Tokyo, Japan) and further disinfected by 3Mix-MP placed on the dentine floor of the cavities. 3Mix-MP was not placed directly onto exposed pulp. Patients were not anesthetized with local anesthesia, because the above procedures do not give pain to patients. Under anesthetized conditions, dentists may not recognize damaging the pulps and giving pain to patients.

Once the access preparation was completed, a 1 mm diameter ball-like particle of 3Mix-MP preparation was placed onto the bottom of the restoration cavity, and, using a cotton ball, pressed to a thin layer on the cavity floor. Then, a first layer of glass-ionomer cement (Fuji IX, GC, Tokyo) was applied to seal 3Mix-MP with care not to express 3Mix-MP out of the cavity. The cavity was then entirely sealed with the second layer of glass-ionomer cement. Then, a widely open-angled restoration cavity for a composite resin-inlay restoration was made as small in size as possible. The wider margin areas on enamel were provided to reinforce the seal and to ensure sufficient adherence and retention of the composite resin-inlay restoration following etching with 35% phosphoric acid solution. The resin-inlay, made using the Clearfil composite resin (Kuraray, Tokyo, Japan) on the tooth, was cemented using the Panavia F 2.0 Estenia Cementing Kit (Kuraray, Tokyo, Japan) according to the manufacturer's manual. In certain cases with undermined cusps, an onlay form of the composite resin restoration was provided. In cases with extensive coronal destruction, metal inlays fixed by resin cement were used. In most cases, the treatment was completed in one visit.

Post-treatment observations, including those using post-operative radiographs, were made to assess the changes of the clinical symptoms. Vitality of pulp was checked by electronic method using a Pulp Detector (Dentotest, Medinale, Zürich, Switzerland). Pulp sensations evoked by cold and hot stimuli were also confirmed. In addition, any pain or discomfort on biting or chewing on the treated tooth was noted.

The three clinical outcomes were defined as follows. A "good" clinical outcome was defined as the lack of any spontaneous pain, no mechanical allodynia to biting and the presence of pulpal responsiveness to cold or electrical stimuli. An outcome of pulpal necrosis was defined by the lack of pulpal responsiveness to cold or electrical stimuli, although no clinical symptoms and no mechanical allodynia to biting were observed. Thus, these cases were clinically good and no further treatment was needed. The outcome of "root canal re-treatment" was defined as the presence of symptoms at the follow-up visit; these cases were treated with a second application of 3Mix-MP.

### Results

A total 360 cases is included in the present study, and all were diagnosed as pulpitis, because they had either radiographically evident carious dentin extending to the pulp chamber (264 cases; 73 %), clinically evident pulp exposure

**Table 1. Clinical outcomes of 3Mix-MP pulpitis treatment**

Clinical Outcome	Cases with spontaneous pain	Cases without spontaneous pain	Total
Good	222 (95%)	120 (94%)	342 (95%)
Necrotic	2 (1%)	4 (3%)	6 (1%)
Root Canal re-treatment	9 (4%)	3 (2%)	12 (3%)
Total	233	127	360

**Table 2. Clinical outcomes of pulpitis cases with spontaneous pain**

Clinical Outcome	Occasional Pain (%)	Pain at Night	Continuous pain	Total
Good	179 (96%)	12 (86%)	31 (97%)	222 (95%)
Necrotic	2 (1%)	0 (0%)	0 (0%)	2 (1%)
Root Canal re-treatment	6 (3%)	2 (14%)	1 (3%)	9 (4%)
Total	187	14	32	233

**Table 3**

Clinical outcomes of cases with spontaneous pain with or without pulp exposure

Clinical Outcome	Cases with Pulp Exposure (%)	Cases without Pulp Exposure	Total
Good	35 (92%)	187 (96%)	222 (95%)
Necrotic	1 (2%)	1 (0.5%)	2 (1%)
Root Canal re-treatment	2 (4%)	7 (4%)	9 (4%)
Total	38	195	233

(78 cases; 22%) or spontaneous pain (233 cases; 65%). Some cases were comprised of a combination of these criteria (Fig. 1). Nearly all cases (357 of 360) were vital as defined by a positive pain sensation to a cold stimulus. About 30% of the cases (130 of 360) had mechanical allodynia as defined as pain to percussion with such a mirror handle.

Of the 264 cases with carious lesions extending to pulps, 262 (99%) were hypersensitive to cold water, 74 (28%) had exposed pulps, 95 (36%) had mechanical allodynia, 139 (53%) complained of spontaneous pain, and 28 (11%) had periradicular radiolucent areas. Out of 233 cases with spontaneous pain, 231 (99%) were hypersensitive to cold water, 38 (16%) had exposed pulps, 139 (60%) had carious lesions extending to pulps, 110 (57%) had mechanical allodynia, and 23 (10%) had periradicular radiolucent areas. Among these 233 patients, 187 (80%) complained of occasional spontaneous pain, 14 (6%) reported spontaneous pain at night, and 32 (14%) had experienced continuous spontaneous pain including pulsing pain.

Out of 78 cases with clinically exposed pulps, all were hypersensitive to cold water, 23 (29%) had mechanical allodynia, 38 (49%) complained spontaneous pain, and 6 (8%) had periradicular radiolucent areas.

Patients were periodically examined for post-operative findings several times when the patients visited the clinic and the final follow-up examination was done 123–2065 days after the treatment. As shown in Table 1, 342 (95%) cases out of 360 cases, treated with LSTR 3Mix-MP therapy, were classified as having a good outcome, because the pulps were vital and the patients could bite on the teeth without discomfort when evaluated more than one month after the treatment. An additional 12 (3%) cases required a second application of 3Mix-MP due to an initial failure to resolve symptoms; these

cases were associated with poor margins on the composite restorations, and all subsequently met the criteria for a good outcome. An additional 6 cases were justified as pulpal necrosis (dead pulps), and no clinical symptoms and discomfort were reported, meaning that the cases, as the dental treatment, were successful. Thus, the dead pulps after disinfected did not show any clinical symptoms and no further treatment was given.

We next evaluated various subsets of the 360 cases to determine if prognostic factors were evident that could predict the clinical outcome. Treatment with LSTR 3Mix-MP was classified as good regardless of the presence of spontaneous pain (Table 1) or the temporal nature of the pain report (Table 2). In addition, the clinical outcome of cases with spontaneous pain and either the presence of absence of a clinically evident visual pulp exposure was similar (Table 3). Finally, the presence of radiographic carious lesions extending to the pulp (Table 4) or clinically evident carious exposure of the pulp (Table 5) did not alter the outcome of the 3Mix-MP treatment. It should be noted that these excellent clinical outcomes were obtained even though carious dentin including softened dentin was intentionally left in all cases. Visibly exposed holes to pulps were not extended any more intentionally, and, instead, pulp tissue was disinfected with 3Mix-MP placed on overlying dentin with closure of the exposing hole with glass-ionomer cement, and, as the result, the pulp was kept vital without any clinical symptoms in 91% cases (Table 5).

No other adverse effects were observed in this case series including allergic reactions, a “flare-up” of pain or swelling, or bleeding from the exposed pulps.

The decalcified areas on pre-operative X-ray photographs increased radio-opaque density on post-operative ones apparently, indicating the areas were re-calcified. Although

quantitative differentiation or determination of radio-opaque density was not easy, in most cases (85 %) re-calcification were apparently observed when checked after one year.

**Table 4.** Clinical outcomes of cases with carious dentin extending to the pulp

Clinical Outcome	Cases with Exposed Pulp	Cases without Pulp Exposure	Total
Good	67 (91%)	181 (95%)	248 (94%)
Necrotic	4 ( 5%)	2 ( 1%)	6 ( 2%)
Root Canal re-treatment	3 ( 4%)	7 ( 4%)	10 ( 4%)
Total	74	190	264

**Table 5.** Clinical outcomes of cases with exposed Pulp

Clinical Outcome	Cases with Spontaneous Pain	Cases without Spontaneous Pain	Total
Good	35 (92%)	36 (90%)	71 (91%)
Necrotic	1 ( 3%)	3 ( 8%)	4 ( 5%)
Root Canal re-treatment	2 ( 5%)	1 ( 2%)	3 ( 4%)
Total	38	40	78

## Discussion

It has been reported that bacteria can invade pulp tissue even under conditions of shallow carious lesions or when clinically intact dentin still remains (2). This indicates that bacteria can invade not only through a visible exposed holes opened to pulp chamber but also through certain dentinal tubules beneath caries cavities, and inflammation and/or infection of pulp may occur even in early stage of dentin caries. One implication of this finding is that complete elimination of bacteria may require resection of a rather large area of dentin. However, this may weaken tooth structure or expose the pulp tissue. Even so, bacteria may be present beneath any subsequent restoration with eventual induction of pulpitis (25).

In the present study, we selected cases of pulpitis with carious dentin extending to the pulp, as evidenced by radiographic examination. Cases with exposed pulps and cases with spontaneous pain also included in this study. It is likely that bacteria or their byproducts, may have already invaded the pulp tissue with subsequent inflammatory or immune host responses (2). The conventional treatment of cases classified as having "irreversible pulpitis" is to surgical remove the pulp by a pulpectomy procedure. However, the LSTR hypothesis proposes that the local application of antimicrobial agents, such as the 3Mix-MP combination evaluated in the present retrospective study, would disinfect these lesions by eradicating bacteria in dentinal or pulpal lesions. The results in the present clinical study support this concept since >90% of cases fulfilling the criteria of "irreversible" pulpitis were classified as having a good long-term outcome after local application of 3Mix-MP. In addition, we note prior short-term studies where cases of irreversible pulpitis were symptomatically controlled and remained vital after systemic steroid injection (26). Interestingly, this systemic steroid treatment led to significantly reduced pulpal levels of inflammatory mediators (27), suggesting that clinically

significant pulpal blood flow remains even in cases diagnosed as having irreversible pulpitis. Taken together, these findings suggest that the definition of so-called irreversible pulpitis should be reconsidered. We definitely call this pulpitis treatment as LSTR 3Mix-MP SavePulp therapy, because most inflamed pulps were saved to be alive instead of the removal of pulp tissue in the conventional endodontic therapy.

The LSTR hypothesis predicts a successful clinical outcome by local bacterial eradication. In addition to the treatment of pulpitis cases that are reported in the present study, permanent teeth (21) and primary teeth (24) with periradicular lesions have been also successfully treated by 3Mix-MP endodontic therapy. These might indicate that 3Mix-MP therapy may have broad applications for endodontic treatment by creating conditions for pulpal healing, revascularization or control of infection. For example, it is also possible to provide revisionary endodontic treatment (i.e. "re-treatment") of cases with 3Mix-MP without removal of previous root canal obturating materials (Takushige & Hoshino, unpublished data).

The results of this retrospective clinical study indicate that LSTR therapy using 3Mix-MP, a mixture of metronidazole, ciprofloxacin and minocycline (3Mix), and macrogol and propylene glycol (MP), provided excellent clinical outcomes in treatment of cases with caries dentin extended to pulps, cases with exposed pulps and cases of pulpitis with spontaneous pain. These data provide a strong rationale for conducting prospective randomized clinical trials and offer the potential for a new model for treating infections of the pulpodentin complex.

## References

- Hoshino E: Predominant obligate anaerobes in human carious dentin. *J Dent Res* 1985; 64: 1195-8.
- Hoshino E, Ando N, Sato Mi, Kota K: Bacterial invasion of non-exposed dental pulp. *Int Endod J* 1992; 25: 2-5.
- Ando N, Hoshino E: Predominant obligate anaerobes invading the deep layers of root canal dentine. *Int Endod J* 1990; 23: 20-7.
- Sato T, Hoshino E, Uematsu H, Noda T: Predominant obligate anaerobes in necrotic pulps of human deciduous teeth. *Microb Ecol Health Dis* 1993; 6: 269-75.
- Kiryu T, Hoshino E, Iwaku M: Bacteria invading periapical cementum. *J Endod* 1994; 20: 169-72.
- Hoshino E, Sato Mi, Sasano T, Kota K: Characterization of bacterial deposits formed in vivo on hydrogen-ion-sensitive field transistor electrodes and enamel surfaces. *Jap J Oral Biol* 1989; 31: 102-6.
- Hori R, Kohno S, Hoshino E: Tongue microflora in edentulous geriatric denture-wearers. *Microb Ecol Health Dis* 1999; 11: 89-95.
- Hoshino E, Sato Mi: Composition of bacterial deposits on full denture. *Jap J Prosthet Dent* 1988; 32: 762-6 (in Japanese with English Abstract).
- Sato Ma, Hoshino E, Nomura S, Ishioka K: Salivary microflora of geriatric edentulous persons wearing dentures. *Microb Ecol Health Dis* 1993; 6: 293-9.
- Uematsu H, Hoshino E: Predominant obligate anaerobes in human periodontal pockets. *J Periodont Res* 1992; 27: 15-9.
- Hoshino E, Echigo S, Yamada T, Teshima T: Isolation of *Propionibacterium acnes* from sclerosing osteomyelitis of mandibles. *Jap J Oral Biol* 1984; 26: 48-51.
- Nakazawa F, Hoshino E: Phylogenetic diversity among unknown oral bacterial species. *J Oral Biosci* 2005; 47: 52-9.
- Hoshino E, Kota K, Sato Mi, Iwaku M: Bactericidal efficacy of metronidazole against bacteria of human carious dentin in vitro. *Caries Res* 1988; 22: 280-2.
- Hoshino E, Iwaku M, Sato Mi, Ando N, Kota K: Bactericidal efficacy of metronidazole against bacteria of human carious dentin in vivo. *Caries Res* 1989; 23: 78-80.
- Hoshino E, Sato Mi, Uematsu H, Kota K: Bactericidal efficacy of metronidazole against bacteria of human periodontal pockets in vitro. *Jap J Oral Biol* 1991; 33: 483-9.
- Sato T, Hoshino E, Uematsu H, Kota K, Iwaku M, Noda T: Bactericidal efficacy of a mixture of ciprofloxacin, metronidazole,

minocycline and rifampicin against bacteria of carious and endodontic lesions of human deciduous teeth in vitro. *Microb Ecol Health Dis* 1992; 5: 171-7.

17. Sato T, Hoshino E, Uematsu H, Noda T: In vitro antimicrobial susceptibility to combinations of drugs of bacteria from carious and endodontic lesions of human deciduous teeth. *Oral Microbiol Immunol* 1993; 8: 172-6.

18. Sato I, Kurihara-Ando N, Kota K, Iwaku M, Hoshino E: Sterilization of infected root-canal dentine by topical application of a mixture of ciprofloxacin, metronidazole and minocycline in situ. *Int Endod J* 1996; 29: 118-24.

19. Hoshino E, Kurihara-Ando N, Sato I, Uematsu H, Sato Mi, Kota K, Iwaku M: In-vitro antimicrobial susceptibility of bacteria taken from infected root dentine to a mixture of ciprofloxacin, metronidazole and minocycline. *Int Endod J* 1996; 29: 125-30.

20. Hori R, Kohno S, Hoshino E: Bactericidal eradication from carious lesions of prepared abutments by an antibacterial temporary cement. *J Prosthet Dent* 1997; 77: 348-52.

21. Takushige T, Hoshino E: Clinical evaluation of 3Mix-MP method in

endodontic treatment. *Jap J Conserv Dent* 1998; 41: 970-4 (in Japanese with English Abstract).

22. Cruz EV, Kota K, Huque J, Iwaku M, Hoshino E: Penetration of propylene glycol through dentine. *Int Endod J* 2002; 35: 330-6.

23. Hoshino E, Takushige T: LSTR 3Mix-MP method. Better and efficient clinical procedures of Lesion Sterilization and Tissue Repair (LSTR) therapy. *DentalReview* 1998; 666: 57-106 (in Japanese).

24. Takushige T, Cruz EV, M Asgor M, Hoshino E: Endodontic treatment of primary teeth using a combination of antibacterial drugs. *Int Endod J* 2004; 37: 132-8.

25. Brännström M: *Dentin and Pulp in Restorative Dentistry*. Nacka, Dental Therapeutics AB; 1981.

26. Gallatin E, Reader A, Nist R, Beck M: Pain reduction in untreated irreversible pulpitis using an intraosseous injection of Depo-Medrol. *J Endod* 2000; 26:633-8.

27. Isett J, Reader A, Gallatin E, Beck M, Padgett D: Effect of an intraosseous injection of depo-medrol on pulpal concentrations of PGE2 and IL-8 in untreated irreversible pulpitis. *J Endod* 2003; 29: 268-71.

**Correspondent:**

Professor HOSHINO Etsuro

Oral Ecology in Health and Infection,

Niigata University Graduate School of Medical and Dental Sciences

Gakkocho-dori 2, Niigata 951-8514 Japan

Fax: +81 (0)25-227-0806; Tel: +81 (0)25-227-2838; e-mail: hoshino@dent.niigata-u.ac.jp

---

Supported by the Grants-in-aid for Scientific Research (14406028, and 17390500) from the Ministry of Education, Culture, Sports, Science and Technology, and by the grants for the Joint Research Program from the Japan Society for the Promotion of Science.

---

